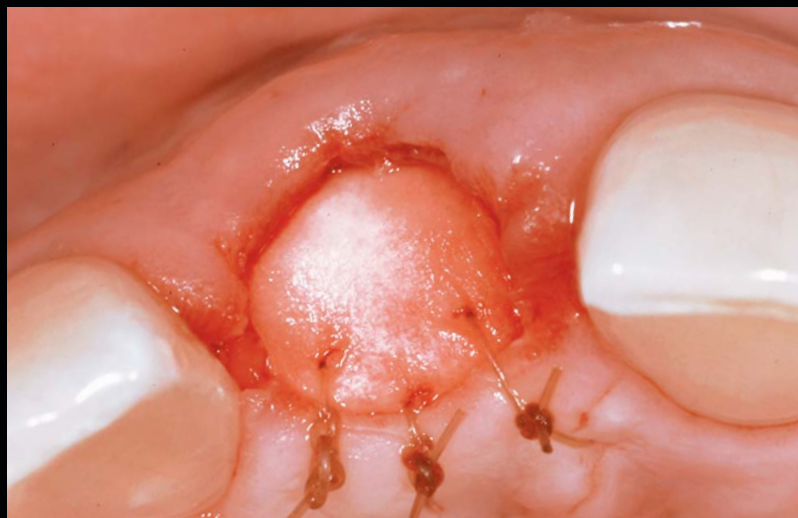

# A SIMPLIFIED SOCKET CLASSIFICATION AND REPAIR TECHNIQUE

Nicolas Elian, DDS\* • Sang-Choon Cho, DDS, MS† • Stuart Froum, DDS‡  
Richard B. Smith, DDS§ • Dennis P. Tarnow, DDS||



*Clinicians are often confronted with changes in the anatomy of the local site following tooth extraction. Successful management of the extraction socket can be challenging, particularly in the aesthetic zone. Proper management is necessary to ensure that the implant used to support a prosthesis will remain stable. This article will recommend a classification system for various types of extraction sockets. A simple, noninvasive approach to the grafting and management of sockets when soft tissue is present but the buccal plate is compromised following tooth extraction will also be discussed.*

## Learning Objectives:

This article discusses a classification system for extraction sockets and a noninvasive approach for grafting. Upon reading this article, the reader should:

- Understand the proposed classification system, which addresses three different types of sockets.
- Become more familiar with the steps involved in a socket-repair technique for Type II sockets.

**Key Words:** extraction socket, buccal plate, Type II socket, noninvasive

\* Associate Professor, Division Head of Department of Implant Dentistry, Department of Periodontology and Implant Dentistry, New York University College of Dentistry, New York, NY; private practice, Fort Lee, NJ.

† Clinical Assistant Professor, Department of Periodontology and Implant Dentistry, New York University College of Dentistry, New York, NY; private practice, New York, NY.

‡ Clinical Professor, Department of Periodontology and Implant Dentistry, New York University College of Dentistry, New York, NY; private practice, New York, NY.

§ Fellow, Department of Periodontology and Implant Dentistry, New York University College of Dentistry, New York, NY; private practice, New York, NY.

|| Professor and Chair, Department of Periodontology and Implant Dentistry, New York University College of Dentistry, New York, NY; Section Editor, Periodontology/Implantology, PPAID; private practice, New York, NY.

**Nicolas Elian, DDS, 345 E. 24th Street, New York, NY 10010**  
Tel: 212-998-9421 • E-mail: ne3@nyu.edu

A functional, highly aesthetic implant restoration has become the goal of therapy for both patients and clinicians, which coincides with the greater demand for quicker and less invasive implant procedures. The first step in the transition from a failing tooth to an implant-supported prosthesis is the extraction of the tooth and management of the extraction socket. Various treatment options have been proposed, including extraction with or without socket preservation surgery, immediate implant placement, and delayed implant placement with or without ridge augmentation. Multiple techniques have been used to treat extraction sockets. These techniques range from using full flaps to no flaps to utilizing different types of grafts (if any), bone replacement materials, and membranes (eg, absorbable, nonabsorbable).<sup>1-13</sup>

One of the primary factors determining which treatment to select in the aesthetic zone is the presence and degree of soft tissue recession on the tooth being extracted, and the presence or absence of the buccal plate of bone. Several publications have based treatment recommendation of the socket (ie, immediate or delayed implant placement), with or without augmentation procedures, on the socket morphology following tooth extraction.<sup>14,15</sup> This article presents both a new, simple classification of extraction sockets and an easy non-invasive approach to the grafting of sockets when soft tissue is present but the buccal plate is partially or totally missing after extraction.

### Classification of Extraction Sockets

There have been a number of proposed systems to classify extraction sockets.<sup>14</sup> Some of these are very detailed and intricate for routine clinical use. Following years of

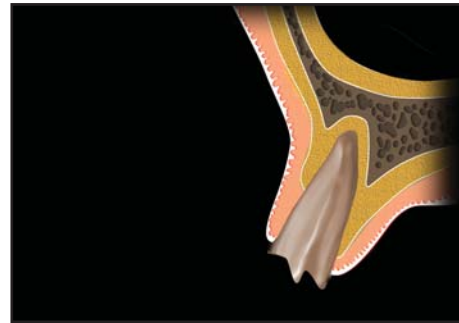


Figure 2. Diagram of a tooth that is diagnosed as hopeless due to incisal trauma.

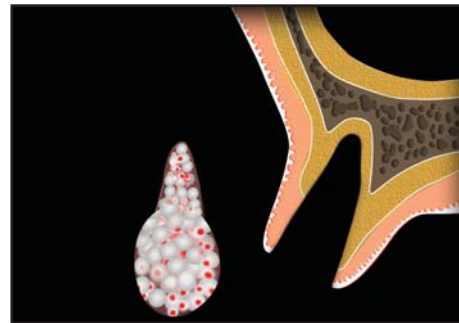


Figure 3. Once the tooth is atraumatically removed, a collagen membrane is contoured into a modified V-shape to fit inside the extraction socket.

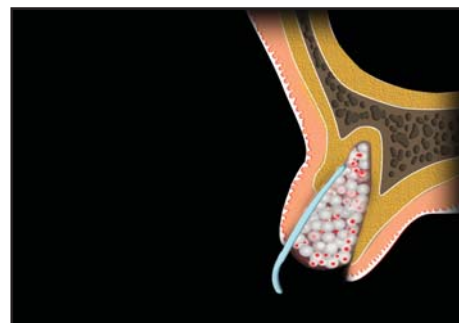


Figure 4. The membrane is positioned in the socket lining the buccal tissues, and graft material is placed.

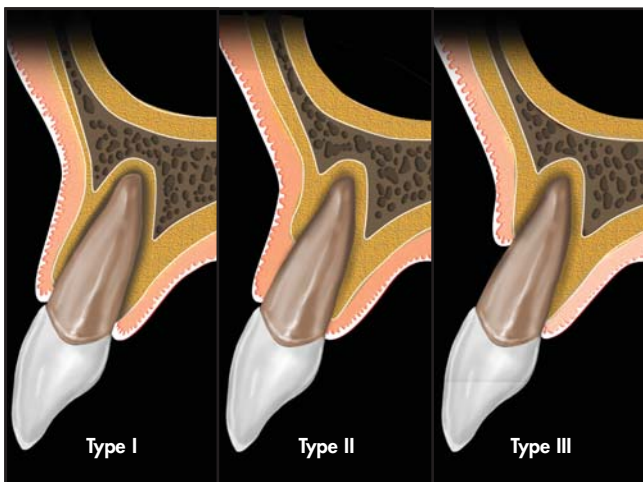
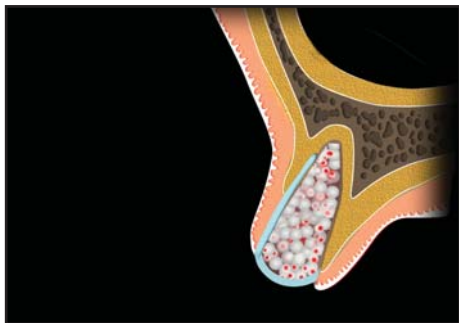
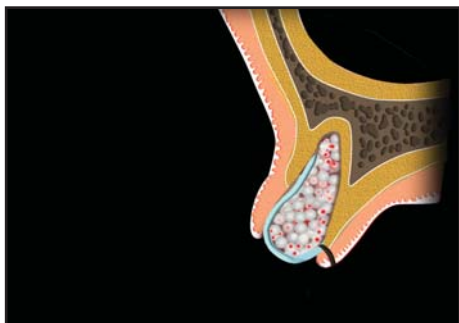


Figure 1. Illustration of the three types of extraction sockets, as defined by the facial soft tissue and buccal plate of bone present.

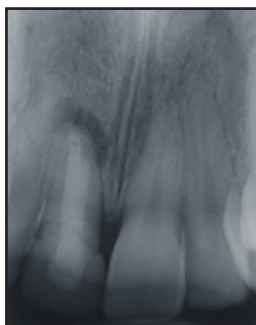
socket research and analysis, it has become obvious to the authors that although there are multiple variables present with every extraction socket, the key factor determining the quality of the socket following extraction is the presence or absence of the buccal hard and soft tissue. Therefore, a new simplified classification will be proposed. This classification should allow easier documentation and better communication between clinicians, researchers, and authors. The classification is divided in to three socket types.



**Figure 5.** The membrane is sutured utilizing absorbable sutures to the palatal tissue.



**Figure 6.** The buccal tissue is prevented from migrating into the healing socket.



**Figure 7.** Patient presented with pain and mobility of tooth #8(11), which was diagnosed as hopeless due to horizontal and vertical root fractures.

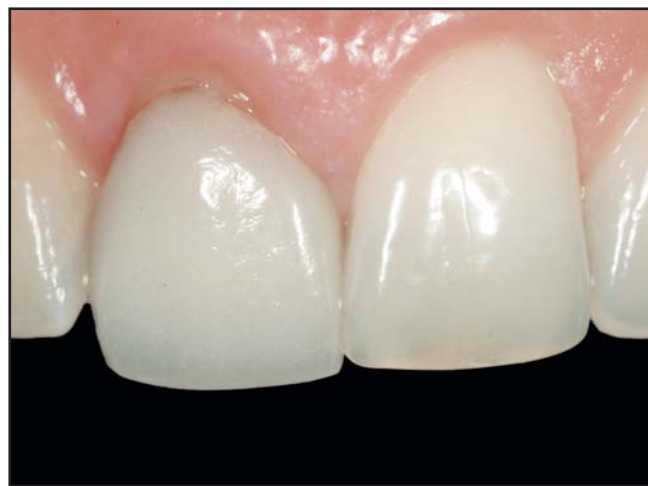- **Type I Socket.** The facial soft tissue and buccal plate of bone are at normal levels in relation to the cementoamel junction of the pre-extracted tooth and remain intact postextraction (Figure 1).
- **Type II Socket.** Facial soft tissue is present but the buccal plate is partially missing following extraction of the tooth.
- **Type III Socket.** The facial soft tissue and the buccal plate of bone are both markedly reduced after tooth extraction.

Type I sockets are the easiest and most predictable to treat. Most of the cases seen demonstrating excellent aesthetics with implants are Type I sockets. This is particularly true if the soft tissue profile is thick and flat as opposed to a highly scalloped, thin profile.<sup>16</sup> Type III sockets, however, are very difficult to treat and require soft tissue augmentation with additional grafts of connective tissue, or connective tissue and bone, in a staged approach to rebuild lost tissue. These cases are associated with soft tissue recession and loss of the buccal plate on the tooth prior to extraction. Sockets in this classification require very high dental experience, skill, and time commitment for success.

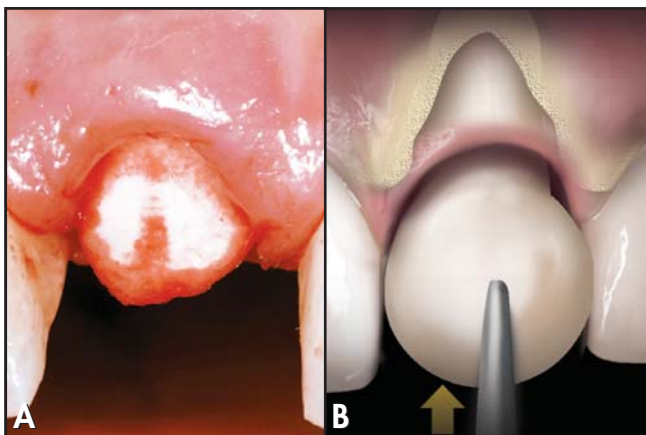
Type II sockets are oftentimes the most difficult to diagnose. These sockets can be very deceptive, as the inexperienced clinician may make the mistake of treating it as a Type I socket. This often leads to a less than ideal aesthetic result. The largest group of aesthetic problems comes from improper treatment of Type II sockets because of the posttreatment soft tissue recession that may occur. This is particularly true when immediate implant placement is performed. Many different procedures have been suggested to treat sockets of this type.<sup>17-19</sup> This article will present a treatment for Type II sockets that should be easier, less complicated, and equally predictable compared to more difficult techniques.<sup>20</sup>

### Rationale for New Socket Repair Technique

The ideal technique for restoring the buccal plate of bone after tooth extraction should be simple, minimally invasive, and preserve the attached gingiva and soft tissue contours. Moreover, this should be achieved with minimal surgery.



**Figure 8.** The defect was classified as Type II. Tissue was present on the facial but not the buccal plate.



**Figure 9A.** The trimmed Socket Repair Membrane (Zimmer Dental, Carlsbad, CA) was adapted in the socket. **9B.** The pre-cut membrane should extend over the facial defect both bilaterally and apically.

The socket repair technique proposed in this article is intended for Type II sockets, where a significant amount of the buccal plate is missing following extraction.

**Step 1.** Once the tooth is diagnosed as hopeless (Figure 2), it is removed atraumatically. This should be performed utilizing flapless extraction with care not to disturb the interproximal papillae and labial soft tissue.

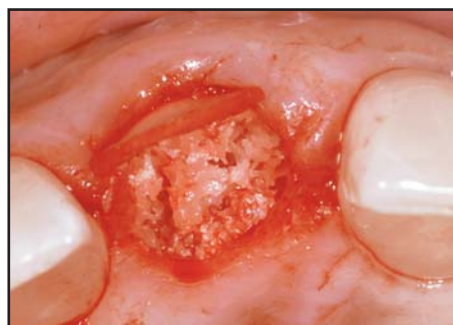**Step 2.** The socket is then debrided with surgical curettes, and any infected tissue is removed. A finger should be placed over the buccal tissue when curetting the buccal part of the socket to prevent perforation of the soft tissue.

**Step 3.** A collagen membrane is contoured into a modified V-shape (Figure 3). The membrane should be strong so that it can be sutured and maintain a long absorption time to allow for guided bone regeneration. The membrane must also be firm enough to allow insertion into the socket without collapsing. The barrier used with this technique is an absorbable collagen membrane that can be sutured without tearing. The narrow part of the trimmed membrane (ie, a V-shaped cone) is placed into the socket and should be wide enough to extend laterally past the defect in the buccal wall. Placing the membrane on the external aspect of the buccal wall could compromise its blood supply and cause an increased chance of resorption. The wider part of the membrane should be trimmed and be able to cover the opening of the socket following graft placement.

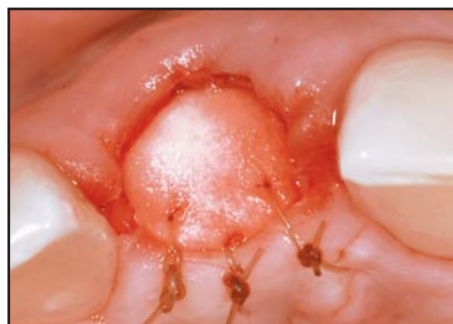**Step 4.** Following final shaping, the membrane is positioned into the socket lining the buccal tissues. The socket is then filled with a bone graft; pressure from the graft against the membrane will help keep it in place and push out the contour of the buccal tissue (Figure 4). Ideally, the graft material should be compressed into the socket and remain in place. The graft material recommended

for this technique is a small-particle, mineralized cancellous freeze-dried bone allograft (ie, 0.25 mm to 1 mm). This graft material should be hydrated for five minutes and retain enough moisture for the particles to aggregate when inserted. This allograft material compresses well and, because it is mineralized, slowly resorbs. It also helps keep the shape of the socket while new bone repopulates and fills the socket during healing.

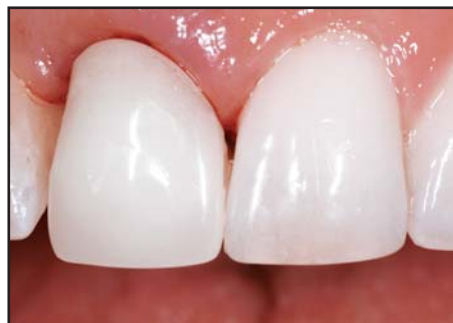**Step 5.** After the graft is compressed, the top part of the membrane is extended over the opening of the socket. The membrane is then sutured with two or three



**Figure 10.** Compressed small particle graft (ie, Puros, Zimmer Dental, Carlsbad, CA) in place within the socket.



**Figure 11.** Once the graft material was placed, the soft tissue was sutured palatally with 5-0 absorbable sutures.

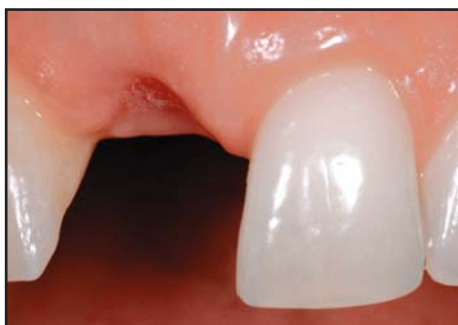

**Figure 12.** A removable “flipper” was placed with no pressure on the membrane.

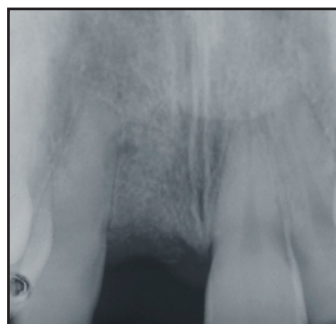
5-0 absorbable sutures to the palatal tissue (Figure 5). No sutures are needed on the buccal aspect since the membrane is kept in place from the pressure of the graft against the buccal tissue.

### Discussion

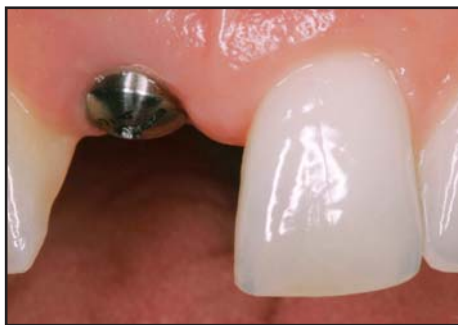This minimally invasive technique satisfies the critical requirements needed for socket repair. By not reflecting or coronally advancing the buccal flap, there is no change in the mucogingival junction (MGJ) position. This is



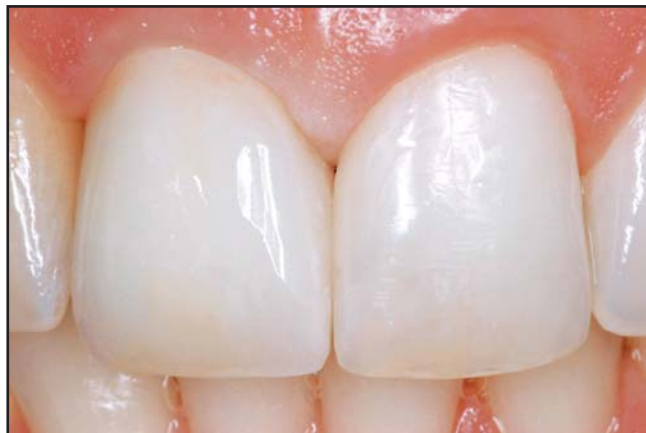**Figure 13.** Facial view of the socket two weeks following tooth extraction.



**Figure 14.** Radiograph of the socket site two months postextraction.



**Figure 15.** Facial view of the treatment site six months following extraction.



**Figure 16.** Postoperative view of the definitive implant-supported crown restoration demonstrates natural aesthetics and integration.

particularly important in the aesthetic zone, where coronal advancement of the MGJ often requires subsequent apical repositioning with additional surgery following socket healing to re-establish a band of keratinized tissue on the buccal aspect of the implant and ideal MGJ.

In considering use of the membrane in this technique, it is important for the practitioner to understand how the objectives of guided bone regeneration and socket preservation differ. In the former, the goal is formation of new bone. In socket preservation, however, the goal is to maintain both hard and soft tissue levels. The purpose of the membrane is to contain the graft, which in turn prevents invasion of soft tissue into the socket.

By placing the membrane inside the socket, the periosteum is not detached from the remaining buccal plate, which will occur if a flap is reflected exposing the buccal plate. The clinician is still able to push the buccal tissues facially by compressing the graft properly. Therefore, the buccal tissue contours are not compromised. Moreover, placing the membrane inside the socket before the graft is placed results in particle containment and maintains the soft tissue morphology. The buccal tissue is prevented from migrating into the healing socket and, therefore, bone cells from the socket walls can now repopulate the defect forming new bone (Figure 6). Placement of the membrane in the socket covers a portion of the buccal wall. This allows the other three walls to contribute to the repopulation of the socket and healing of the graft. The absorbable membrane will block the overlying soft tissue from repopulating the defect. It will then resorb over a period of four months, preventing soft tissue from the buccal aspect (in the area of the defect) from penetrating into the graft material.

The coronal part of the membrane that is left exposed will start to resorb over the course of the first

two weeks after placement. This membrane serves as a graft containment and as protection for the initial clot. Some coronal particles of the graft occasionally migrate out of the socket, but the remaining part of the graft and the membrane that is covered by the buccal tissue will still be available to form new bone in the socket. Timing of implant placement should be determined by the size of the buccal wall defect; the larger the defect, the more time that is needed. The minimum time needed is usually four to six months for the bone to fill in.

The classification presented in this article allows the clinicians to determine if socket surgery is necessary and whether an immediate or delayed implant protocol is indicated. Previous classifications focused on socket parameters that would allow immediate implant placement as opposed to the approach indicating augmentation of the defect following extraction and healing.<sup>2,5</sup> The current classification is simple because it easily identifies the socket type and this determines which treatment should be followed (Figures 7 through 16). Type I sockets require no augmentation and can be treated with an immediate or delayed implant approach. Type II and III sockets require socket treatment and should be treated with a staged approach since, following socket healing, additional soft and hard tissue surgery may be necessary prior to implant placement. This allows site preparation to be completed prior to implant placement, which will then produce the best aesthetics possible. This classification also has a biological basis in that the vascular supply to the buccal plate of bone is considered in the overall healing response. This is aimed at maintenance of the buccal plate of bone, which is the essential parameter in determining mid-buccal recession following implant placement. This should increase the predictability of a highly aesthetic final result.

### Conclusion

A new and simplified socket classification and treatment have been presented. This classification is simple, based on the presence or absence of buccal hard and soft tissue following tooth extraction, and is valuable clinically as a method of determining socket treatment options and timing of implant placement. This minimally invasive socket repair technique has the advantage of being flapless, not distorting the buccal and interproximal tissue contours, preserving the height of the MGJ, and allowing for the reformation of the buccal plate of bone. Thus, comparison of bone levels prior to and following treatment should be a goal of future studies with this technique. Nevertheless, the technique is not complicated and may be easily used in combination with the extraction of any tooth.

### Acknowledgment

*The authors declare no financial interest in any of the products referenced herein.*

### References

1. Gelb DA. Immediate implant surgery: 3-year retrospective evaluation of 50 consecutive cases. *Int J Oral Maxillofac Impl* 1993;8:388-399.
2. Garber DA, Belsler UC. Restoration-driven implant placement with restoration-generated site development. *Compend Cont Educ Dent* 1995;16(8):796-804.
3. Salama H, Salama M. The role of orthodontic extrusive remodeling in the enhancement of soft and hard tissue profiles prior to implant placement: A systematic approach to the management of extraction site defects. *Int J Perio Rest Dent* 1993;13(4):312-333.
4. Meltzer AM. Non-resorbable-membrane-assisted bone regeneration: Stabilization and the avoidance of micromovement. *Dent Impl Update* 1995;6(6):45-48.
5. Tinti C, Parma-Benfenati S. Clinical classification of bone defects concerning the placement of dental implants. *Int J Perio Rest Dent* 2003;23(2):147-155.
6. Sclar AG. The Bio-Col Technique. In: *Soft Tissue and Esthetic Considerations in Implant Therapy*. Carol Stream, IL: Quintessence Publishing Co; 2003:75-112.
7. Landsberg CJ. Socket seal surgery combined with immediate implant placement: A novel approach for single-tooth replacement. *Int J Perio Rest Dent* 1997;17(2):140-149.
8. Garber DA, Salama MA, Salama H. Immediate total tooth replacement. *Compend Contin Educ Dent* 2001;22(3):210-218.
9. Becker W, Dahlin C, Becker BE, et al. The use of ePTFE barrier membranes for bone promotion around titanium implants placed into extraction sockets: A prospective multicenter study. *Int J Oral Maxillofac Impl* 1994;9(1):31-40.
10. Boyne PJ. Use of HTR in tooth extraction sockets to maintain alveolar ridge height and increase concentration of alveolar bone matrix. *Gen Dent* 1995;43(5):470-473.
11. Brugnami F, Then PR, Moroi H, et al. GBR in human extraction sockets and ridge defects prior to implant placement: Clinical results and histologic evidence of osteoblastic and osteoclastic activities in DFDBA. *Int J Perio Rest Dent* 1999;19(3):259-267.
12. Carmagnola D, Adriaens P, Berglundh T. Healing of human extraction sockets filled with Bio-Oss. *Clin Oral Implants Res* 2003;14(2):137-143.
13. Lekovic V, Camargo P, Klokkevald P, et al. Preservation of alveolar bone in extraction sockets using bioabsorbable membranes. *J Periodont* 1998;69(9):1044-1049.
14. Saadoun AP, Landsberg CJ. Treatment classifications and sequencing for postextraction implant therapy: A review. *Pract Periodont Aesthet Dent* 1997;9(8):933-941.
15. Schropp L, Kostopoulos L, Wenzel A. Bone healing following immediate versus delayed placement of titanium implants into extraction sockets: A prospective clinical study. *Int J Oral Maxillofac Impl* 2003;18(2):189-199.
16. Kan JY, Rungcharassaeng K, Umezaki K, Kois JC. Dimensions of peri-implant mucosa: An evaluation of maxillary anterior single implants in humans. *J Periodont* 2003;74(4):557-562.
17. Becker W, Dahlin C, Becker BE, et al. The use of ePTFE barrier membranes for bone promotion around titanium implants placed into extraction sockets: A prospective multicenter study. *Int J Oral Maxillofac Impl* 1994;9(1):31-40.
18. Becker W, Becker B, Polizzi G, Bergstrom C. Autogenous bone grafting of bone defects adjacent to implants placed into immediate extraction sockets in patients: A prospective study. *Int J Oral Maxillofac Impl* 1994;9:389-396.
19. Warrer L, Goffredsen K, Hjørring-Hansen E, Karring T. Guided tissue regeneration ensures osseointegration of dental implants placed into extraction sockets. An experimental study in monkeys. *Clin Oral Implants Res* 1991;2(4):166-171.
20. Butler B. Utilizing microsurgical techniques for augmenting the extraction socket. Presented at the 87th meeting of the American Academy of Periodontology, October 6-10, 2001, Philadelphia, PA.

# CONTINUING EDUCATION (CE) EXERCISE No. 4



To submit your CE Exercise answers, please use the answer sheet found within the CE Editorial Section of this issue and complete as follows: 1) Identify the article; 2) Place an X in the appropriate box for each question of each exercise; 3) Clip answer sheet from the page and mail it to the CE Department at Montage Media Corporation. For further instructions, please refer to the CE Editorial Section.

The 10 multiple-choice questions for this Continuing Education (CE) exercise are based on the article "A simplified socket classification and repair technique," by Nicolas Elian, DDS, Sang-Choon Cho, DDS, MS, Stuart Froum, DDS, Richard B. Smith, DDS, and Dennis P. Tarnow, DDS. This article is on Pages 99-104.

- 1. What is the first step in the transition from a failing tooth to an implant-supported prosthesis?**
  - a. The extraction of the tooth.
  - b. The management of the extraction socket.
  - c. Neither a nor b.
  - d. Both a and b.
- 2. Type III sockets are very difficult to treat and often require which of the following?**
  - a. A very high degree of dental experience.
  - b. Skill.
  - c. Time commitment for success.
  - d. All of the above.
- 3. What makes up the ideal technique for restoring the buccal plate of bone after tooth extraction?**
  - a. It should be simple.
  - b. It should be minimally invasive.
  - c. It should preserve the attached gingiva and soft tissue contours.
  - d. All of the above.
- 4. What is done to the socket in Step 2 of the New Socket Repair Technique?**
  - a. The socket is debrided with surgical curettes.
  - b. The tooth is removed atraumatically.
  - c. A collagen membrane is contoured into a modified V-shape.
  - d. None of the above.
- 5. What classifies a socket as a Type III Socket?**
  - a. The facial soft tissue is present and not reduced after extraction.
  - b. The facial soft tissue and buccal plate are reduced after extraction.
  - c. The buccal plate is partially missing following extraction of the tooth.
  - d. The facial soft tissue and buccal plate are at normal levels.
- 6. After the graft is compressed, which part of the membrane is extended over the opening of the socket?**
  - a. The bottom of the membrane.
  - b. The side of the membrane.
  - c. The top of the membrane.
  - d. No part of the membrane is extended over the socket.
- 7. A collagen membrane is contoured into what modified shape?**
  - a. A modified U-shape.
  - b. A modified V-shape.
  - c. A modified O-shape.
  - d. A modified C-shape.
- 8. The goal of guided bone regeneration is the formation of new bone. The goal of socket preservation is to maintain both hard and soft tissue levels.**
  - a. The first statement is true.
  - b. The second statement is true.
  - c. Both statements are true.
  - d. Neither statement is true.
- 9. How many weeks after placement will the coronal part of the membrane that is left exposed start to resorb?**
  - a. Two weeks.
  - b. Five weeks.
  - c. Seven weeks.
  - d. Four weeks.
- 10. Timing of implant placement should be determined by the size of the buccal wall defect. The smaller the defect, the more time that is needed.**
  - a. The first statement is true.
  - b. The second statement is true.
  - c. Neither statement is true.
  - d. Both statements are true.